



# A Rare Presentation of Tuberculosis: Multifocal Skeletal and Multisystemic Disease Evaluated with Imaging Findings

BURAK GÜNAY

BÜŞRA ÖZDEMİR

FETHİ EMRE USTABAŞIOĞLU

\*Author affiliations can be found in the back matter of this article

IMAGES IN CLINICAL  
RADIOLOGY

]u[ubiquity press

## ABSTRACT

**Teaching point:** Tuberculosis (TB) is a rare clinical disease in the musculoskeletal system. Multifocal bone involvement and multisystemic spread of this disease is extremely uncommon and difficult to diagnose.

CORRESPONDING AUTHOR:

**Fethi Emre Ustabasıoğlu**

Assistant Professor,  
Department of Radiology,  
Trakya University Faculty of  
Medicine, TR

[ustabasioglu@hotmail.com](mailto:ustabasioglu@hotmail.com)

KEYWORDS:

multisystemic; multifocal;  
skeletal; tuberculosis;  
treatment

TO CITE THIS ARTICLE:

Günay B, Özdemir B, Ustabasıoğlu FE. A Rare Presentation of Tuberculosis: Multifocal Skeletal and Multisystemic Disease Evaluated with Imaging Findings. *Journal of the Belgian Society of Radiology*. 2022; 106(1): 14, 1-3. DOI: <https://doi.org/10.5334/jbsr.2679>

## CASE HISTORY

A 27-year-old female patient was admitted to Trakya University Hospital with a history of recurrent fever, weight loss, and intermittent lumbar back pain lasting for one month. The patient also reported persistent headache, chills, and night sweats. She has no history of TB exposure or chronic lung disease. Cranial and lumbar magnetic resonance imaging (MRI), thoracic and lumbar computed tomography (CT), and whole-body 18F-FDG PET/CT were taken upon her complaints (*Figures 1–3*).

Based on the symptoms and the examinations, metastatic disease or bone tuberculosis was suspected. Subsequently, to make the definitive diagnosis, open biopsy was performed under the L2 lamina and L2

vertebral bodies. Histopathological examination showed local sequestrum formation. Langerhans cells were detected with giant cells and dead bones, which are the characteristic features of TB disease.

## COMMENT

In this case report, which showed unusual radiological findings that were more indicative of malignancy or metastatic disease, a rare case of atypically disseminated multifocal skeletal and multisystemic TB was identified. Thus, due to the complex and atypic clinical findings of multifocal skeletal TB, it is easy to misdiagnose the disease [1].

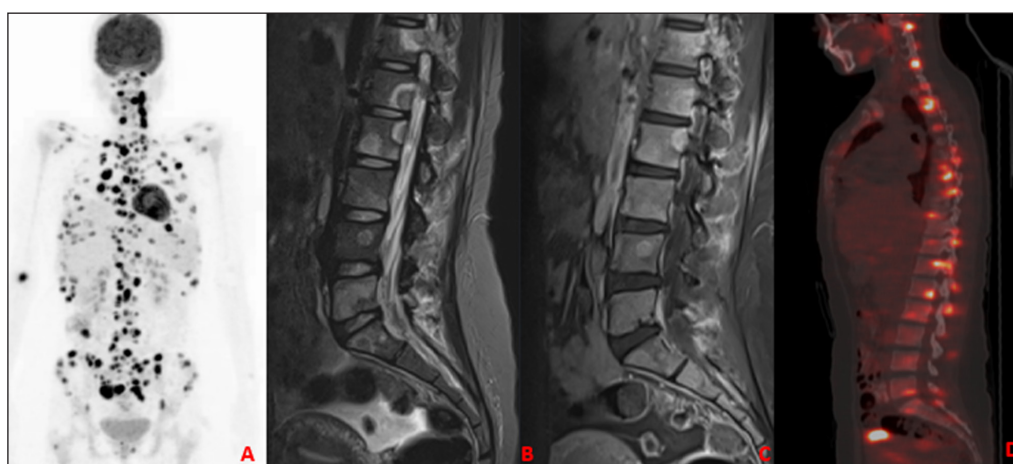


Figure 1.

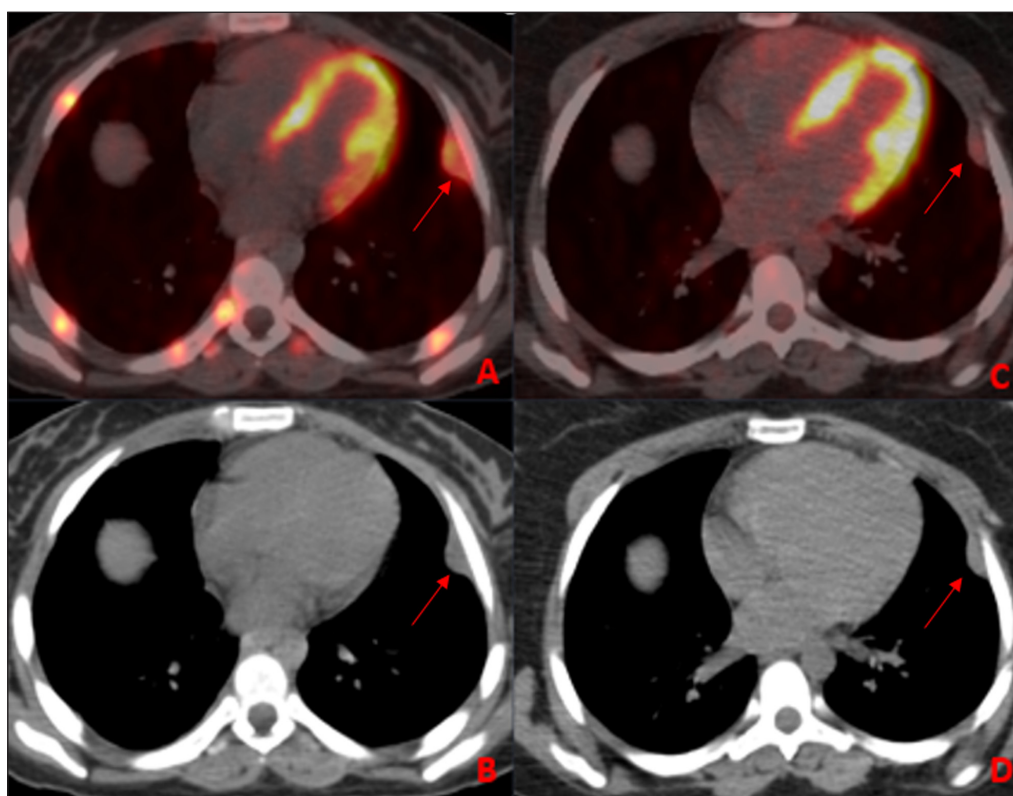


Figure 2.

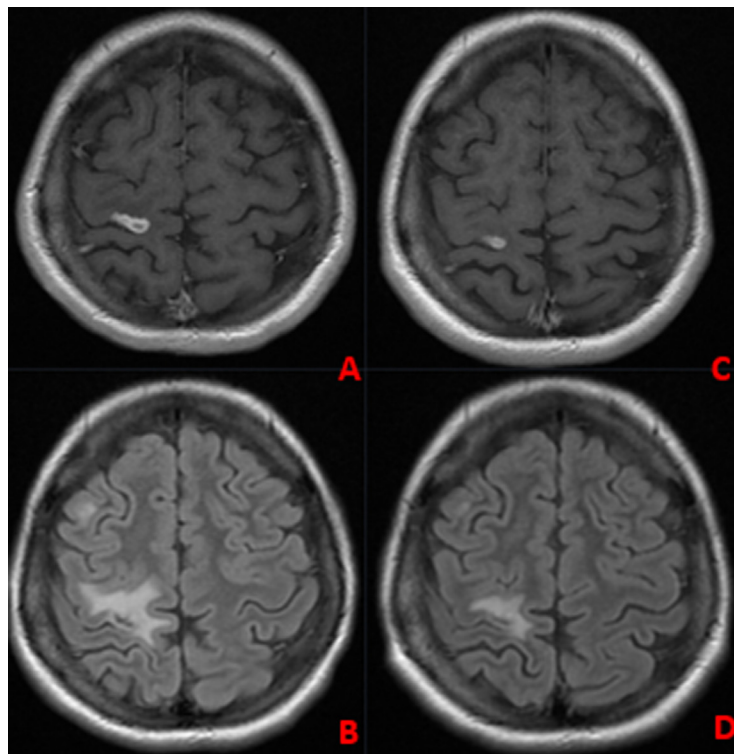


Figure 3.

## FUNDING INFORMATION

The authors have no relevant financial interest in this article.

## COMPETING INTERESTS

The authors have no competing interests to declare.

## AUTHOR AFFILIATIONS

**Burak Günay**  [orcid.org/0000-0002-8462-7681](https://orcid.org/0000-0002-8462-7681)

Radiology resident, Department of Radiology, Trakya University Faculty of Medicine, TR

**Büşra Özdemir**  [orcid.org/0000-0001-8540-0115](https://orcid.org/0000-0001-8540-0115)

Nuclear Medicine Resident, Department of Nuclear Medicine, Trakya University Faculty of Medicine, TR

**Fethi Emre Ustabaşoğlu**  [orcid.org/0000-0002-0340-4487](https://orcid.org/0000-0002-0340-4487)

Assistant Professor, Department of Radiology, Trakya University Faculty of Medicine, TR

## REFERENCE

1. **Zhang L**, et al. Multifocal skeletal tuberculosis: A case report. *Exp Ther Med*. 2016; 11(4): 1288–1292. DOI: <https://doi.org/10.3892/etm.2016.3032>

## TO CITE THIS ARTICLE:

Günay B, Özdemir B, Ustabaşoğlu FE. A Rare Presentation of Tuberculosis: Multifocal Skeletal and Multisystemic Disease Evaluated with Imaging Findings. *Journal of the Belgian Society of Radiology*. 2022; 106(1): 14, 1–3. DOI: <https://doi.org/10.5334/jbsr.2679>

Submitted: 16 October 2021 Accepted: 24 March 2022 Published: 07 April 2022

## COPYRIGHT:

© 2022 The Author(s). This is an open-access article distributed under the terms of the Creative Commons Attribution 4.0 International License (CC-BY 4.0), which permits unrestricted use, distribution, and reproduction in any medium, provided the original author and source are credited. See <http://creativecommons.org/licenses/by/4.0/>.

*Journal of the Belgian Society of Radiology* is a peer-reviewed open access journal published by Ubiquity Press.