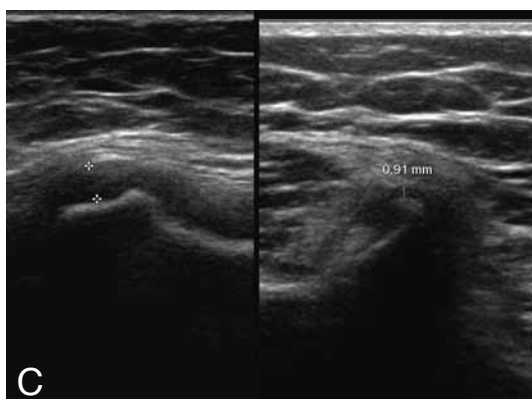
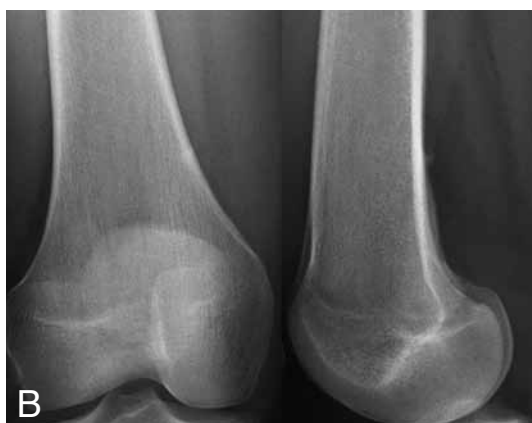
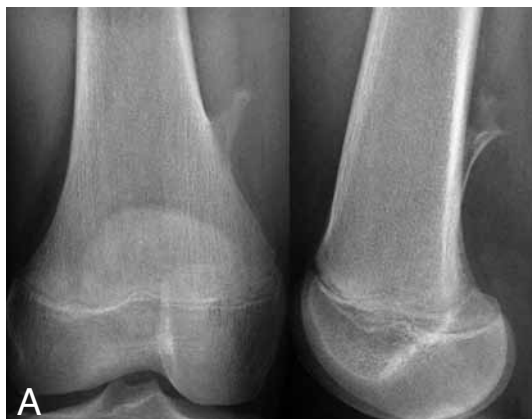
## IMAGES IN CLINICAL RADIOLOGY



### *Solitary osteochondroma: spontaneous regression*

F.C. Deprez, M. Beltrán-Marín, J. Malghem, R. Menten, P. Clapuyt<sup>1</sup>

A 15-year-old female had been followed in our department of pediatric radiology since the age of 11, in order to control a solitary osteochondroma (exostosis) of the right distal femur.

Radiographs of the right distal femur (face-profile) and high frequency ultrasound studies (12-5 MHz) of this area were performed to assess the size of the lesion and the thickness of the cartilaginous cap.

Follow up of the lesion showed an increase in size from the age of 11 to the age of 12 with a cartilaginous cap thickness of 3 mm. Coincident with a growth plate closure a thinning of the cartilaginous cap was documented by ultrasounds, reducing from 3 mm to < 1 mm at the age of 13 (Fig. C. Cartilaginous cap of the osteochondroma at the age of 12 - C1 - and 15 years - C2). A spontaneous regression of the osteochondroma occurred in the following years ranging from the age of 13 (Fig. A) to the age of 15 (Fig. B).

#### *Comment*

Osteochondromas, or exostoses, are the most frequent benign bone tumors in children. Osteochondromas are histologically characterized by a cartilage-caped bony outgrowth, developed on the metaphyses of long bones. Osteochondromas can be isolated (85%) or multiple (15%, in autosomal dominant hereditary osteochondromatosis).

Spontaneous regression of osteochondroma is well known but very rare. It can be observed with sessile or pediculated osteochondromas. Mechanisms of osteochondromas regression remain unknown. The period of resolution ranges from 6 months to 6 years, and always seems to occur before the end of the patient growth. Some authors suggest that tumour could be progressively incorporated into the cortex after the end of its growth, others suggest that it could be an active process of resorption and metaphyseal remodeling. Post-traumatic or micro-traumatic remodeling could equally play a role.

At our knowledge, it is the first case reporting a decrease in thickness of the osteochondroma cartilage cap preceding the osteochondroma regression. Dahlin pointed out that an osteochondroma that has stopped growing has practically no cartilage in his cap. Since osteochondroma growth is due to endochondral ossification on the basal surface of hyaline cartilage cap, spontaneous involution of this cap could logically be necessary for the end of the tumour growth, and eventually for the tumour involution, but is probably not a sufficient condition to explain the regression of the osteochondroma.

We would like to remember that ultrasound is the easiest and the cheapest way to assess and follow the thickness of an osteochondroma cartilage cap, especially in the pediatric population.

For information, the first case of spontaneous regression of an osteochondroma was described in 1835 by Hunter, and the first report in the PubMed database was done in 1960 by Sellink J.L., in *J Belge Radiol*, 43: 177-9.

#### *Reference*

1. Valdivielso-Ortiz A., Barber I., Soldado F., Aguirre-Canyadell M., Enriquez G.: Solitary osteochondroma: spontaneous regression. *Pediatr Radiol*, 2010, 40: 1699-1701.

<sup>1</sup>. Department of Radiology, Cliniques Universitaires St-Luc, Brussels, Belgium.